

ST maps

Graphic tool for displaying the spatial
orientation of ST deviations

Introduction

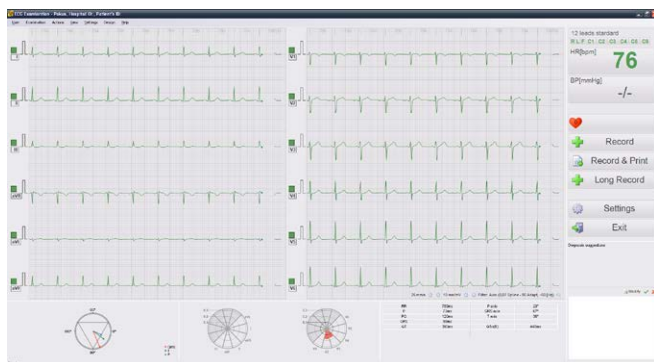Since the ST-segment analysis gives highly valuable information about a patient’s heart condition, it is a matter of high importance to have effective supportive tools for its clear observation and recording. The BTL CardioPoint software offers the ST map component in its Resting ECG and Stress-test modules. This is a graphic tool that allows the quick analysis of myocardial infarction or ischemia. In developing this tool, BTL has compiled all of the recent 2009 AHA/ACCF/ HRS guidelines.

What are ST maps?

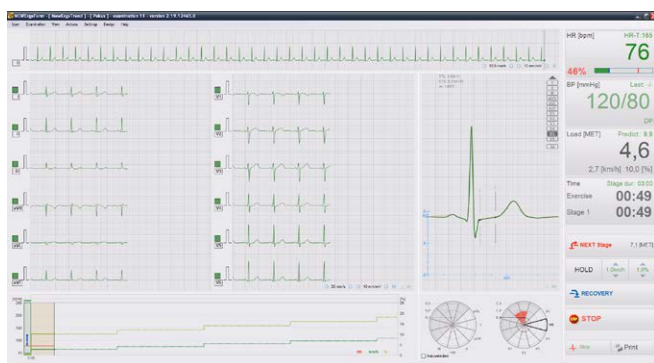
ST maps are a graphic tool for displaying the spatial orientation of ST deviations. There are actually two different ST maps; the left one which represents the vertical heart section and the right one which represents the horizontal heart section. The sequence of leads in the vertical plane is given using the Cabrera system, so that the display reflects the actual orientation of each lead.

Vertical (frontal) ST map - Displays the limb leads and informs about the changes in the area of inferior (diaphragmatic) wall (ECG in leads II, III and aVF) and anterolateral wall of the left ventricle (ECG in leads I and aVL).

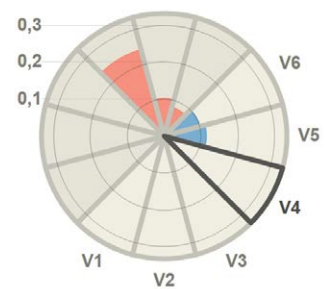
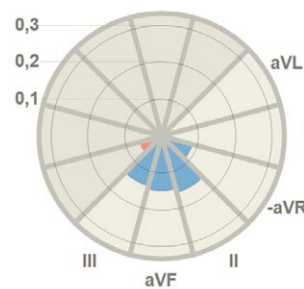
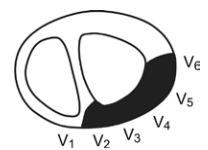
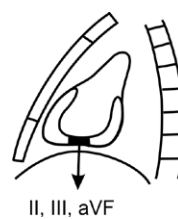
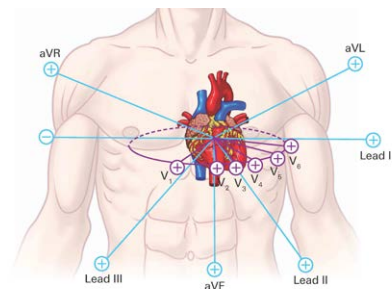
Horizontal (top) ST map – Displays chest leads and informs about the changes (myocardial ischemia, myocardial infarction) of the anterior wall (ECG in leads V1 – V4) and anterolateral wall of the left ventricle (ECG in leads V5 – V6).



The ST map component in **Resting ECG module** of the BTL CardioPoint software



The ST map component in **Stress-test ECG module** of the BTL CardioPoint software



Vertical map

Horizontal map

ST maps show the real orientation of ECG leads.

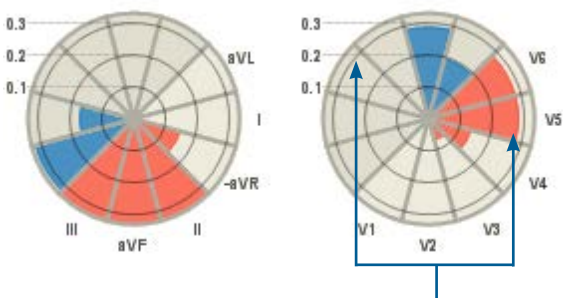
How does it work?

GENERAL:

Each map is formed by 2 colors, 2 semi-circles (each with 6 segments) and 3 radial areas. A red colour represents the ST elevation and blue represents the ST depression. The higher the ST deviation, the larger the colored area is at the respective lead. The ST map is divided into 2 semi-circles - the upper and lower one. The lower semi-circle is divided into 6 sectors marked according to corresponding leads. The upper semicircle with its 6 sectors represents a mirror image of the same leads. The ST map is also divided into three radial sections, which define the depression (elevation) level. 0,1 means the ST deviation is 0,1 mV (1mm). 0,2 means the ST deviation is 0,2 mV (2mm). Finally, 0,3 means the ST deviation is 0,3 mV (3mm).

RESTING ECG:

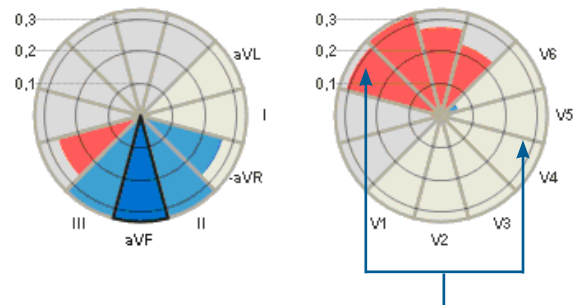
During the recording of a resting ECG, ST maps can be favorably utilized; especially for the quick classification of heart attacks and other serious diseases connected with a shift of the ST segment. The diagram shown in both maps unequivocally identifies the position and extent of the heart damage. The elevations always appear in the lower area, while depressions in the upper one.



Both parts represent the same lead. If the upper part is colored, then a depression occurs in the signal. If the lower part is colored, then there is an elevation in the corresponding lead. Depressions are always marked with blue and elevations with red.

STRESS-TEST ECG:

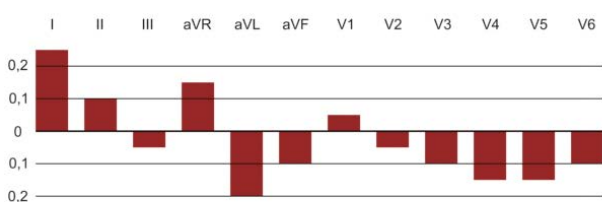The ST maps are particularly helpful for quick determination of ischemia diseases. The image appearing in the maps clearly identifies the position and extent of affected area. A red colour means an ST elevation and blue means depression. The bigger the ST deviation, the bigger the colored area is at corresponding lead. In contrary to the resting ECG, during the stress-test the elevations always go up (upper sector), while the depressions go down (lower sector).



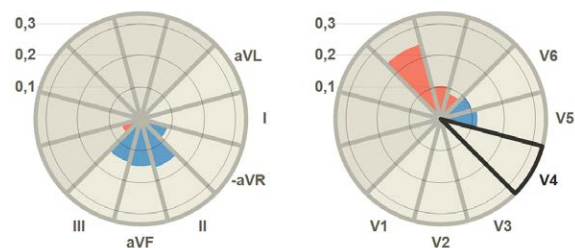
Both parts represent the same lead. If the upper part is colored, then an elevation occurs in the signal. If the lower part is colored, then there is a depression in the corresponding lead. Depressions are always marked with blue and elevations with red.

Advantages

The classic way of graphing an ST segment representation is using a bar graph. However, a bar graph only shows the amplitudes. The information about spatial orientation is completely missing.

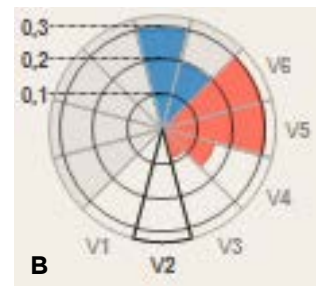
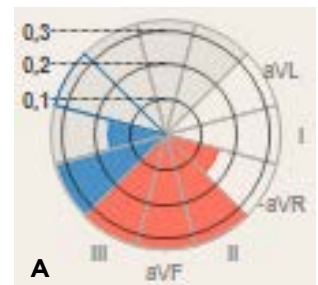
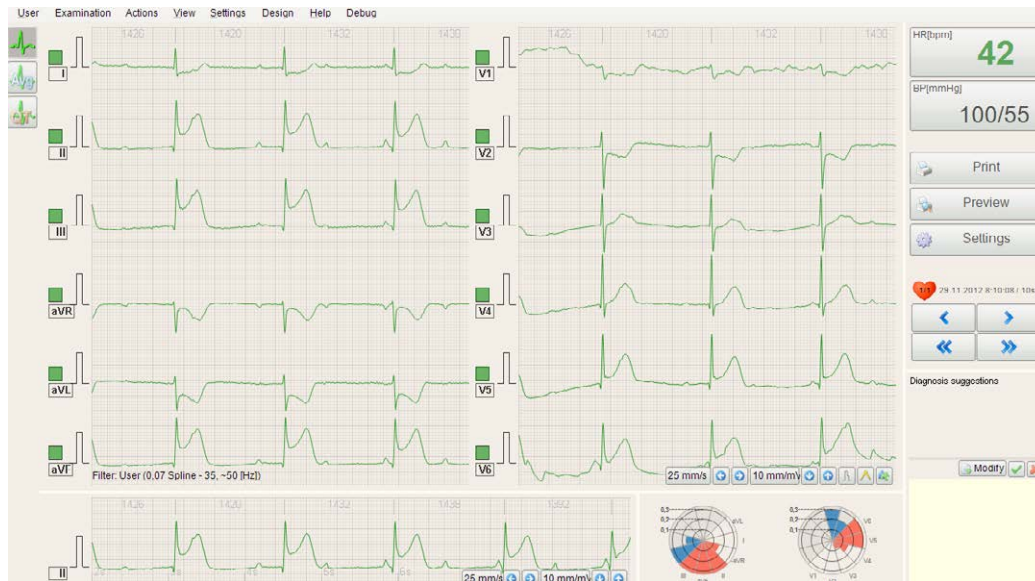

Bar graph only shows the amplitudes, while an ST map shows the amplitudes and the affected areas



Examples

ACUTE INFEROLATERAL MYOCARDIAL INFARCTION:



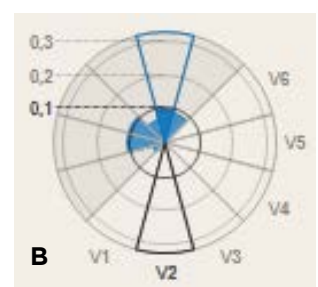
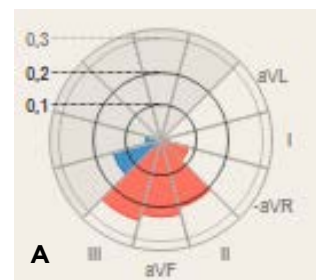
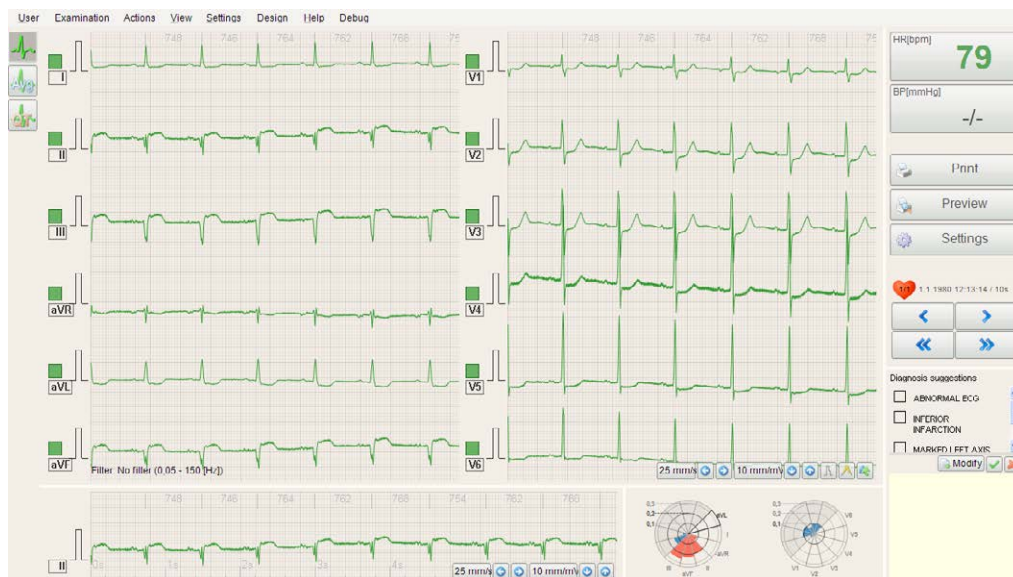
A – VERTICAL MAP

- Significant (over 0,3 mm) ST elevation in leads II, a VF and III corresponds to damaged diaphragmatic wall.
- In the opposite leads I and aVL there is a reciprocal depression.

B – HORIZONTAL MAP

- The elevations in V6, V5, V4 and V3 reflects a damaged lateral and apical wall.
- In the opposite V2 and V1 leads there is a reciprocal ST depression

ACUTE INFERIOR AND POSTERIOR MYOCARDIAL INFARCTION:



A – VERTICAL MAP

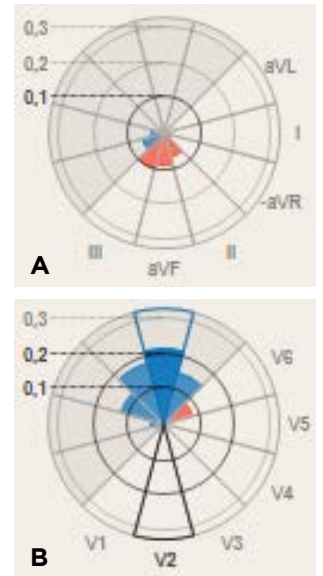
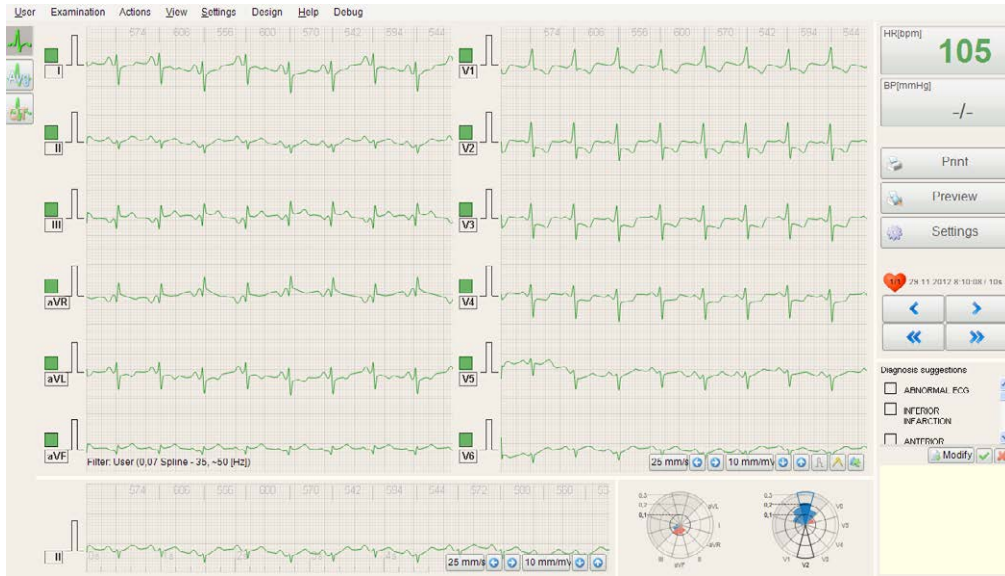- Significant (over 0,2 mm) ST elevation in leads II, aVF and III corresponds to damaged inferior diaphragmatic wall.
- In the opposite leads I and aVL there is a reciprocal depression.

B – HORIZONTAL MAP

- The reciprocal deviations in leads V1, V2, V3 and V4 reflect a damaged posterior diaphragmatic wall of the left ventricle.

Examples

ACUTE INFEROLATERAL MYOCARDIAL INFARCTION:



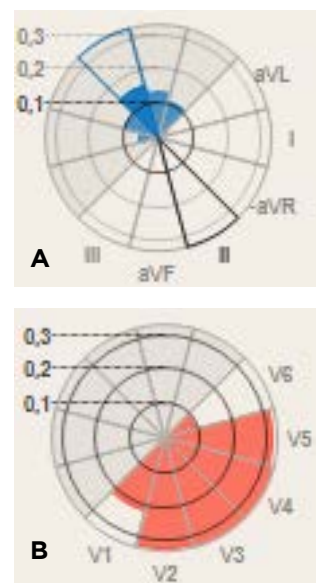
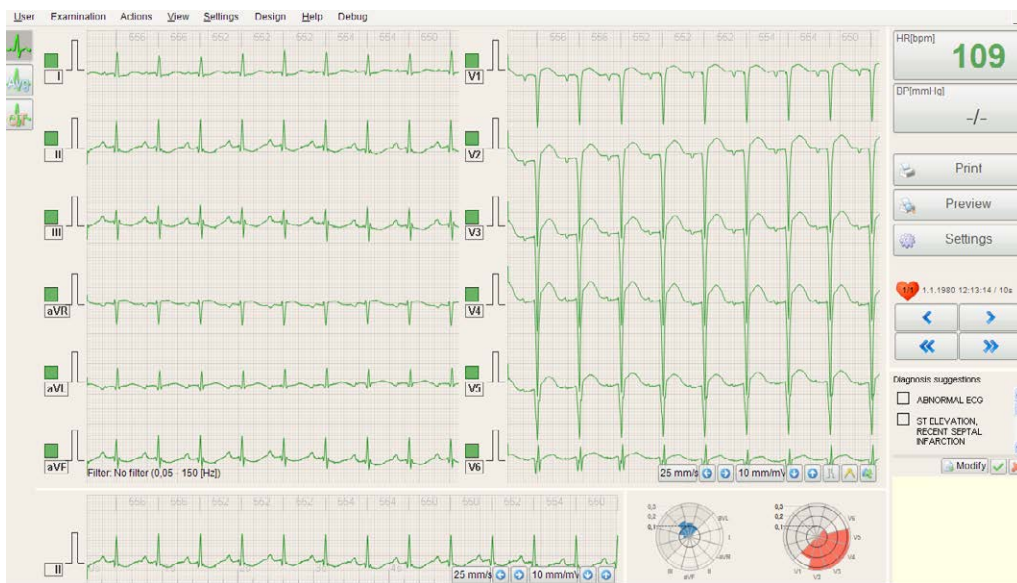
A – VERTICAL MAP

- Mild ST elevation in leads II, aVF and III.
- In the opposite leads I and aVL there is a reciprocal depression.

B – HORIZONTAL MAP

- The reciprocal deviations in leads V1, V2, V3 and V4 reflect a posterior diaphragmatic myocardial infarction.

EXTENSIVE ACUTE MYOCARDIAL INFARCTION OF THE LEFT VENTRICLE (SEPTAL, APICAL, LATERAL). INFERIOR MYOCARDIAL INFARCTION:



A – VERTICAL MAP

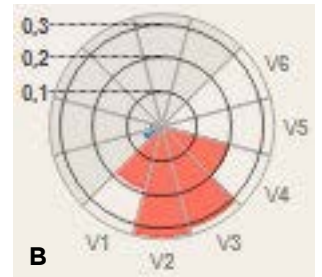

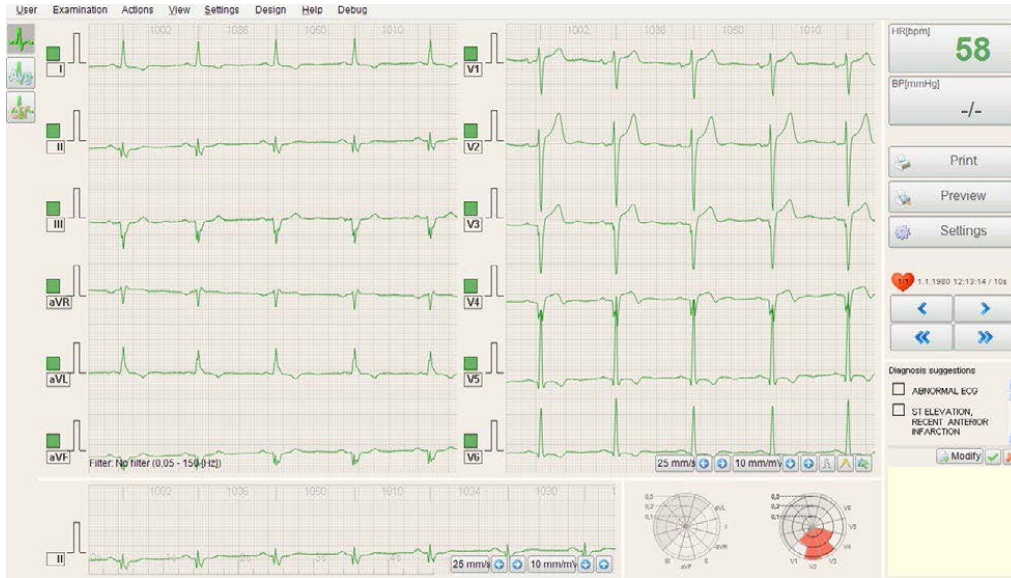
- Mild ST depression in leads II, aVF and III.

B – HORIZONTAL MAP

- Huge ST elevation in chest leads V1, V2, V3, V4 and V5. Mild ST elevation in V6.

Examples

ACUTE ANTEROAPICAL AND OLD INFERIOR MYOCARDIAL INFARCTION:



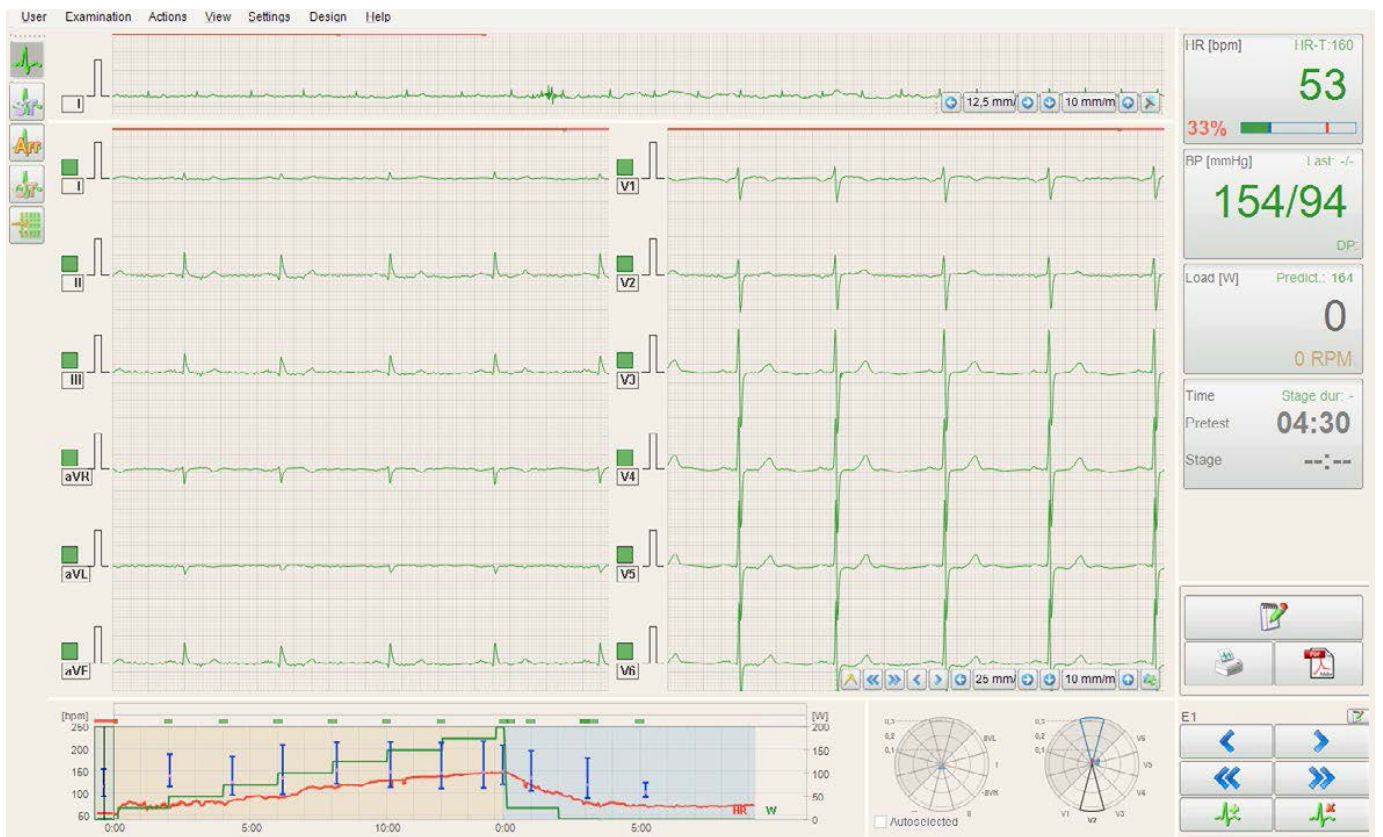A – VERTICAL MAP

- Slight depression in leads aVL, I, aVR and II.

B – HORIZONTAL MAP


- ST elevation in V1, V2, V3 and V4.

STRESS-TEST EXAMINATION RECORD. POSITIVE TEST WITH CORONARY INSUFFICIENCY. CONTINUOUS ST DEPRESSION DEVELOPMENT IN V4 - V6 DURING THE TEST, WHICH IS MOST APPARENT IN RECOVERY PHASE:




Examples

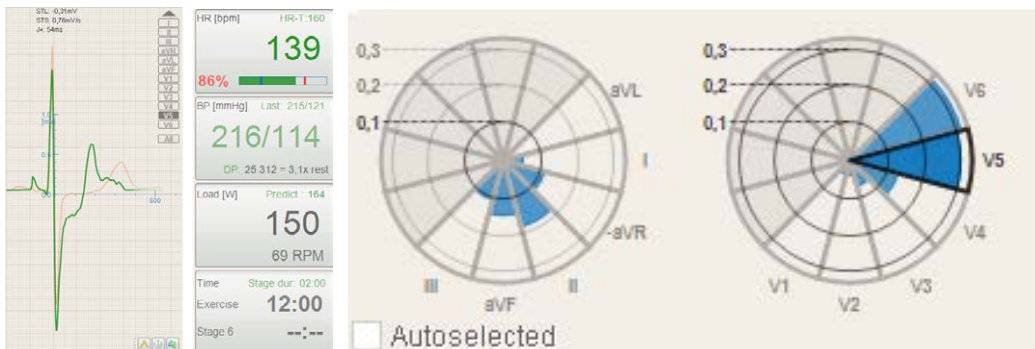
PRE-EXERCISE PHASE: NO ST DEVIATIONS:



STAGE 4 OF THE LOAD PROTOCOL: ST DEPRESSION ALMOST 0.2 MV IN V5—V6:



STAGE 6 OF THE LOAD PROTOCOL: ST DEPRESSION IN II, AVF AND III BELOW 0,2 MV AND ST DEPRESSION OVER 0,3 MV IN V5—V6:



RECOVERY PHASE: ST DEPRESSION OVER 0,2 MV IN V5 - V6:

